

Research Paper—Zoology



March, 2010

SPONTANEOUS PATHOLOGICAL
CHANGES IN TRACHEA OF JAPANESE
QUAIL IN DURG DISTRICT AREA



*USHA SAHU **M. ROY ***N. GUPTA

*Deptt. of Zoology, Govt. V.Y.T.P.G. autonomous College, Durg.

**Deptt. of Zoology, Govt. College, Utai, Durg.

***Deptt. of Pathology, College of Veterinary Science and Animal Husbandry, Anjora, Durg.

A B S T R A C T

*Spontaneous Pathological lesions were observed in the trachea of Japanese Quail (*Coturnix coturnix japonica*) in Durg District area. Out of total 501 samples, 343 (68.46%) samples revealed pathological conditions in different organs. 24 (4.79%) samples showed different pathological changes in trachea. Observation of gross pathological lesions and histopathological studies revealed tracheitis (18 cases, 75%) and hemorrhage in trachea (6 cases, 25%). The pathological conditions observed were Tracheitis and Hemorrhage. Main gross lesions recognized were swollen inner Lining membrane, hyperemia, Increased mucoid secretion, congestion, desquamation of the columnar epithelium, Infiltrations of leukocytes, sloughing off of normal ciliated epithelium, bloody exudates, and Petechial hemorrhage.*

Introduction:

Quails are reared on large scale in Durg District area. They are reared in Govt. Poultry farms as well as by the people in rural areas for flesh and eggs. An ample of work on pathological effects related to various toxicants is available on quail but work on organ pathology due to spontaneous conditions is rare. Infection in respiratory tract is very often lethal for quails. So an attempt is made to investigate the macro and micro histopathological changes associated with tracheal inflammation.

Material and Methods:

Trachea of 501 Quails were observed. Gross lesions were noted and then fixed in 10% formalin for about 72 hrs. Microtomy was done with H&E staining for Histopathological observations.

Pathological conditions in trachea
Tracheitis: 18 (75%) samples revealed tracheitis. Gross Lesions observed were hyperaemic and swollen Lining membrane. Increased mucoid

secretion was observed. Tracheitis is invariably associated with bronchitis. Histopathological changes observed were congestion of blood vessels, swollen and edematous Mucus membrane, Proliferation and patchy desquamation of the columnar epithelium and Infiltrations of leukocytes. Exudates was consisting of mucus desquamated epithelium, few RBC and a few leukocytes. Normal ciliated epithelium was sloughed off.

Gross pathological lesions in trachea are observed by Pradhan *et.al.* (1980), Than *et.al.* (1982) and Jack and reed (1994). A number of workers have reported bronchitis and tracheitis in quail (Pradhan *et.al.* 1980, Chandra and Kumar 1998). Fethy Yilmaz *et.al.* (2004) reported edema, deciliation, necrosis and detachment of tracheal and bronchial epithelium. Swollen epithelial lining, excess mucus secretion in trachea deciliation and desquamation of cells, infiltration of inflammatory cells and necrosis is reported by Thom *et.al.* (1982).

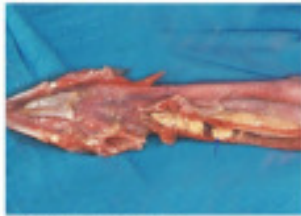

FIG. 21. Showing trachea filled with exudates.

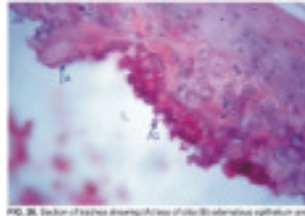


FIG. 26. Section of trachea showing (A) loss of cilia (B) desquamation of epithelium and (C) infiltration of leukocytes. (H & E X 400)

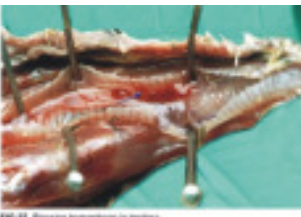

FIG. 22. Showing hemorrhage in trachea.

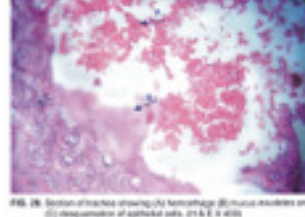
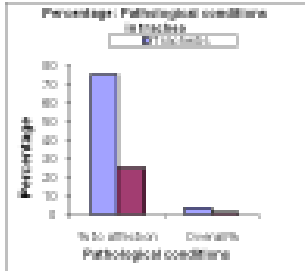
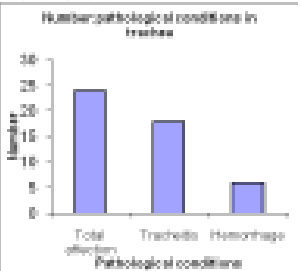


FIG. 25. Section of trachea showing (A) hemorrhage (B) necrosis and (C) desquamation of epithelial cells. (H & E X 400)



Sah *et.al.* (1983) described Increased mucus secretion in trachea due to *P. mirabilis* infection. Jack and Reed (1990) observed Necrosis associated with tracheitis /bronchitis in quail which were experimentally infected with Quail Bronchitis Virus. They have also reported desiliation and desquamation of tracheal and bronchial epithelium and leukocyte infiltration (Jack and Reed 1994). Necrosis in tracheitis is also described by Fethy Yilmaz *et.al.* (2004) in Japanese quails experimentally infected by Avian Influenza Virus. Necrosis is not observed during the investigation. Tracheitis showing caseous

exudates due to *P. multocida* infection is reported by Murakami *et.al.* (2002)

Hemorrhage :

Out of 24 affected trachea 6 samples (25%) showed hemorrhage. Gross Lesions observed were Congestion and petechial hemorrhage. Trecheal lumen was filled with bloody exudates. Histopathologically Epithelial cells

Result and Discussion:

SN	Pathological conditions	Number	Percentage to affection (out of 24) %	Overall percentage (out of 501) %
1.	Tracheitis	18	75	03.59
2.	Hemorrhage	06	25	01.20

number of RBCs. Increased mucus secretion and sometimes-bloody exudates along with loss of cilia and epithelial desquamation of trachea was

observed in hemorrhage in Trachea. Hemorrhage in trachea is quite evident in the present study. Along with mucus secretion, RBCs were also seen. Tracheal lumen was found filled with blood (Jack 1990).

were desquamated, Cilia were lost and Mucus secretions were seen. Exudates contained large

R E F E R E N C E

*Chandra R., and Kumar, (1998). Quail bronchitis., *Pashudhan*, 13:11, 3-5. * Fethy Yilmaz, (2004). Histopathological findings of the Quails Inoculated with Avian influenza A Viruse H7N1 subtype. *International Journal of poultry science*, 3(12) 767. * Jack, S.W., Reed, W.M., (1990). Pathology of Experimentally induced quail bronchitis. *Avian Disease*, 34(1): 44-51. *Jack SW; Reed W.M. ; Burnstein T., (1994). Pathology of quail bronchitis; *Avian Diseases*, 38 (3), 548-56. * Murakami, S., Miyama, M., Shimada, J. and Nakane, T. 2002. Occurrence of * Conjunctivitis, Synositis and Upper region trachitis in Japanese quails. *Avian Pathology*, 31:4, 363-370. * Pradhan,H.K., Mohanty,G.C., Mukit, A., 1985. Marck's Disease in Japanese Quails, a study of Natural Cases. *Div. Avian Dis. Vet. Res Int Izat nagar*. * Sah, R.L., Mall, M.P. Mohanty, G.C.1983. Septisemic protious infection in Japanese Quail chick, *Avian Diseases*, 27:1, 296-300.* Than,V.L., Kneisberg,S., Dixon, B.R., 1982, Cryptosporidiasis in quails. *Avian pathology* 1982; 11:4; 619-626.